

# *Journal of Complementary and Integrative Medicine*

---

*Volume 2, Issue 1*

2005

*Article 5*

---

## **Acute Respiratory Distress Syndrome Successfully Treated with Low Level Laser Therapy**

**Chan Gunn\***

\*Institute for the Study and Treatment of Pain, [istop@istop.org](mailto:istop@istop.org)

Copyright ©2005 by The Berkeley Electronic Press. All rights reserved. No part of this publication may be reproduced, stored in a retrieval system, or transmitted, in any form or by any means, electronic, mechanical, photocopying, recording, or otherwise, without the prior written permission of the publisher, bepress, which has been given certain exclusive rights by the author. *Journal of Complementary and Integrative Medicine* is produced by The Berkeley Electronic Press (bepress). <http://www.bepress.com/jcim>

# Acute Respiratory Distress Syndrome Successfully Treated with Low Level Laser Therapy

Chan Gunn

## Abstract

Acute respiratory distress syndrome (ARDS) is a medical emergency, which may be precipitated by an acute injury to the lung. The injury can also follow direct chest trauma from aspiration of gastric contents or inhalation of toxic gasses. ARDS is not itself a specific disease but a syndrome - a group of symptoms and signs that make up one of the most important forms of respiratory failure.

ARDS is devastating because it can develop quite suddenly in persons whose lungs had been perfectly normal - it kills at least 60% of its victims. The fundamental problem is the sudden appearance of large amounts of fluid in the lung preventing blood from entering the alveoli and decreasing oxygen extraction resulting in hypoxemia.

The tragic feature of ARDS is that it drowns its victim. The appearance of fluid in the lungs - a lethal situation - is from neuro-inflammation.

Important to keep in mind when treating ARDS are: a) Inflammation and Inflammatory exudates Gap Formation, b) Interstitial and Alveolar Inflammation, c) Inflammation and the Nervous System, d) Cholinergic anti-inflammatory pathway.

Neuro-inflammation can be relieved by stimulation of the vagus nerve. Low-level laser therapy, a simple modality with few undesirable side effects, is used to relieve respiratory distress

**KEYWORDS:** ARDS, Low Level Laser Therapy, neuro-inflammation

## INTRODUCTION

Acute respiratory distress syndrome (ARDS) is a medical emergency that may be precipitated by an acute injury to the lung. The injury may be bacterial or viral pneumonia, and can also result from other direct injury to the lung from aspiration of gastric contents or inhalation of toxic gasses. ARDS is not itself a specific disease but a syndrome - a group of symptoms and signs that make up one of the most important forms of respiratory failure.

ARDS is devastating because it can develop quite suddenly in persons whose lungs had been perfectly normal – mortality is at least 60% of its victims. The fundamental problem is the sudden appearance of large amounts of fluid in the lung preventing blood from entering the alveoli to participate in gas exchange. Severe Acute Respiratory Syndrome (SARS), with similar features, also belongs in this category.

Over 100,000 people in the United States die from ARDS each year.<sup>1</sup> The syndrome is poorly understood and there has been little progress in its specific treatment. It is an acute failure of the respiratory system distinguished by fluid buildup inside the lungs, causing stiffening and decreased lung capacity. Dyspnea usually develops within 48 hours. This acute exudative phase, refractory to oxygen therapy, is characteristic of this condition. 4 to 7 days after the onset, a complicated course needing prolonged mechanical ventilation may follow. There is decreased lung compliance, and diffuse infiltrates are seen in chest radiographs which are indistinguishable from cardiogenic pulmonary edema. Symptoms include damage to endothelium and lining of the alveolus, low oxygen concentration in blood despite oxygen supplementation, inflammation of lung cells, and eventually loss of consciousness.<sup>2</sup>

## TREATMENT WITH LOW LEVEL LASER THERAPY - A CASE REPORT:

A patient (68 and previously healthy) was admitted to the Intensive Care Unit on December 28, 1999 with acute respiratory failure secondary to viral pneumonia. Her condition deteriorated rapidly and she required intubation and mechanical ventilation. She was unconscious and ventilated for 30 days.

*12/28/99 - ...moderate right upper lobe collapse and consolidation...air space disease involving the left lower lobe...ill-defined and nodular opacities in the left mid lung...heart not enlarged...no evidence of mediastinal or hilar adenopathy.*

12/29/99 - *Lung volumes have diminished...worsening and more confluent opacification of the left midlung. In addition, new airspace disease in the right middle lobe. The previously described regions of collapse and consolidation in the right upper and left lower lobes have become denser as a result of diminished lung volumes. Overall worsening.*

12/29/99 - *Patient has been intubated ...There is worsening air space disease involving both lungs, which appears worse even though the lung volumes have improved as the result of the intubation. Although distribution would seem in keeping with an infectious etiology, the rapidity of the changes raises the possibility of superimposed non-cardiogenic pulmonary edema.*

She required a tracheotomy and 100% oxygen was administered at the highest level. She developed atrial fibrillation, which required cardioversion and Type II diabetes. When X-rays on 1/2/00 showed no improvement, the attending physician informed her family that the condition was, sadly, irreversible. She was kept alive only by Intensive Care support.

Physical examination revealed her physical signs to be those of radiculopathy involving several segments.<sup>3</sup> For example: atrophy of the small muscles in her hands (C7-8); severe atrophy of the gluteal muscles and decubitus ulcers in the buttocks and left heel (L5, S1-2); trophedema in the subcutaneous tissues of her dorsal and lumbar backs.

Pulmonary edema, like trophedema, is part of the neuropathic disorder. It was decided to use low level laser therapy, a treatment that is sometimes used by physical therapists to soothe inflammation and dissipate edema in soft tissue injury.<sup>4</sup> The laser beam (820nm and 50 mw) was directed between her ribs, into the lungs. It was also directed into paraspinal muscles which overlie the neck and dorsal back, stimulating muscle and nerve roots. Lungs are innervated by nerves from lower cervical and upper dorsal segments.

There was rapid response to stimulation. X-rays taken 6 hours later showed improvement:

1/3/00 - *The consolidative changes in the left upper lobe are slightly reduced. The right upper lobe appears slightly better aerated.*

*The right lower lobe also shows some decrease in the amount of consolidation. Impression: The patient with known diffuse bilateral pneumonia shows slight improvement in the left upper lobe and right lower lobe.*

- 1/7/00 - Both lungs are well ventilated. There is widespread interstitial disease in both lungs. In the left base it has taken a honeycomb pattern. There is no lung contracture.
- 1/15/00 - Both lungs are well ventilated. The interstitial thickening is now localized to the periphery of the right upper zone, right lower zone and left lower zone.
- 1/20/00 - Patchy interstitial thickening in the periphery of both lungs. No consolidation or pulmonary edema.

From commencement of laser therapy, it took 17 days of treatment once daily for 30 minutes to resolve the edema (fluid) in her lungs.

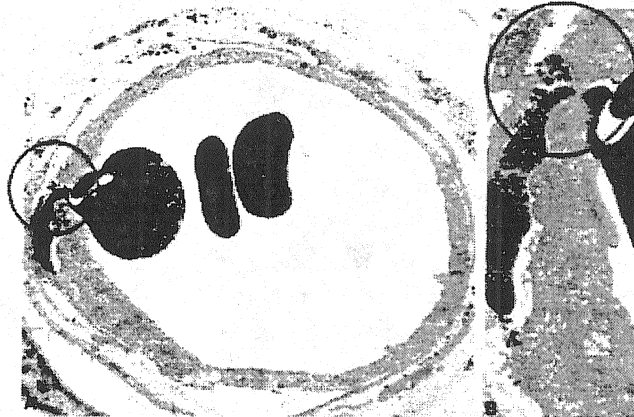
#### DISCUSSION:

The tragic feature of ARDS is that it drowns its victim. The appearance of fluid in the lungs – a lethal situation - is from neuro-inflammation<sup>5, 6, 7</sup>.

***Inflammation and Inflammatory exudate:*** John Hunter had recognized in 1794 that inflammation is a more or less stereotyped response to injury. Therefore similarities can be expected between inflammation in soft tissue and inflammation in lung. Inflammation in soft tissue causes permeability of small blood vessels in and around the injured area to increase. This allows large amounts of fluid and plasma protein to escape into the extravascular space to form inflammatory exudate. Inflammatory exudate is a high-turnover pool of fluid, with a significant amount of protein passing from blood to lymph.<sup>8</sup>

***Permeability and Gap Formation:*** Small molecules are able to rapidly diffuse across the vascular wall, but larger plasma protein can only escape through gaps that appear in the junctions between adjacent endothelial cells. Gap formation, which is initiated by histamine and like substances, is believed to be caused by activation of a contractile protein, similar to actomyosin, within the cytoplasm of endothelial cells. Gap formation is transient and is a reversible

process: when cells come together again, leakage ceases.<sup>9</sup> The aim of treatment is therefore to close the gap.



A large gap is present in endothelium of rat venule. A portion of an erythrocyte lies within the gap (x 5,000). On the right, a magnification (x 15,000).

Adapted from J.F. Hickey, *Inflammation*, Chapter 19, 45  
V.C. Steward & A.F. Taylor, *EBM*, New York, Raven Press, 1994

**Interstitial and Alveolar Inflammation:** When plasma leaks into interstitial and intra-alveolar spaces, it results in alveolar flooding and atelectasis. Epithelial and interstitial cells may proliferate, and collagen accumulates, resulting in severe interstitial fibrosis. These pathologic changes lead to decreased functional residual capacity, ventilation/perfusion mismatch, severe hypoxemia, hypercarbia and pulmonary hypertension.

**Inflammation and the Nervous System:** There is a connection between inflammation and the nervous system. Vertebrates achieve internal homeostasis during infection or injury by balancing the activities of pro-inflammatory and anti-inflammatory pathways.

Inflammation produces molecules that increase blood flow to infected areas and help recruit immune cells. Lipopolysaccharides - components of the cell walls of many bacteria - stimulate macrophages to release powerful pro-inflammatory 'alarm' molecules such as cytokines and Tumour-Necrosis Factor (TNF).<sup>5</sup> TNF at the site of infection is beneficial, but when it enters the systemic blood circulation with bacteria, it can cause sepsis. (TNF is also a mediator of chronic inflammatory disorders such as rheumatoid arthritis and Crohn's disease.)

**Cholinergic anti-inflammatory pathway:** Activation of afferent vagus nerve fibres by endotoxin or cytokine can stimulate hypothalamic-pituitary-

adrenal anti-inflammatory responses.<sup>4</sup> It is now known that the morbidity and mortality caused by TNF can be attenuated by electrical stimulation of the vagus nerve. Stimulation signals act through nicotinic acetylcholine receptor alpha-7 subunit and they rapidly inhibit the release of TNF and cytokines by macrophages.<sup>7</sup> Low-level laser therapy, a simple modality with few undesirable side effects, was used instead of electricity to deliver a source of energy for stimulation of the vagus nerve.

The vagus nerve is part of the autonomic system. There are two autonomic systems: the sympathetic system and the parasympathetic system. Most of the functions of the autonomic nervous system are visceral and widespread. The peripheral autonomic nerves consist mostly of efferent fibers; they are mixed and not purely motor or sensory, some carry secretory fibers as well. The sympathetic system innervates the viscera (intestine, heart, kidney, spleen, etc.), and through the spinal nerves innervates the blood vessels of skin and muscle, pilomotor muscles and sweat glands.

The most important parasympathetic nerve is the vagus, which is widely distributed, and carries the parasympathetic fibers practically everywhere in the body except the head and the limbs. Parasympathetic fibres are abundant in the thoracic and abdominal viscera, for the most part they are provided by the vagus nerve. The vagus carries motor, sensory and parasympathetic nerves and can be stimulated through any of these or through connections with the accessory nerve (trapezius, or sterno-cleidomastoid) and hypoglossal nerve.

#### SUMMARY:

Inflammation generally follows injury, but there is a nervous connection that has been overlooked: part of it is associated with peripheral neuropathy (neuro-inflammation). Neuro-inflammation can be relieved by stimulation of the vagus nerve, but for beneficial effect it is best when stimulation is started early.

This report is a good example of complimentary and integrative medicine at work when regular medicine has failed. Since SARS has similar manifestations, one could conceive of laser therapy having equally effective benefits. Laser therapy may also be applicable to many diseases with similar etiology and pathophysiology.<sup>10</sup>

**REFERENCES**

1. Repine J, Adult Respiratory Distress Syndrome (ARDS): The mystery killer, 2000, Webb-Waring Institute, <http://www.uchsc.edu/sm/waring/webpages/secondlevel/science/ards.html>
2. ARDS (adult respiratory distress syndrome), Health Illustrated Encyclopedia. ADAM, 2004, <http://netwellness.org/ency/article/000103.htm>
3. Gunn, CC, Editor Loeser JD, Chapter 28 Neuropathic Mayofascial Pain Syndromes, Bonica's Management of Pain, 2001, Lippincott Williams & Wilkins, Philadelphia, Third Edition, 522-529
4. Borovikova LV, et al, Vagus nerve stimulation attenuates the systemic inflammatory response to endotoxin, Nature, Volume 405(6785), 25 May 2000, 458 – 462,
5. Libert C, Inflammation: A nervous connection, Nature, 421, 2003, 328-329
6. Tracey KJ, The Inflammatory Reflex, Nature, Volume 420, 19 December 2002, 853-859
7. Wang H, Yu M, Ochani M, et al, Nicotinic acetylcholine receptor 7 subunit is an essential regulator of inflammation, Nature, Volume 421, 23 January 2003, 384-388
8. Pontinen PJ, Low Laser Therapy As A Medical Treatment Modality, 1992, Art Upo, Tampere.
9. Hurley JV, Editors, Staub and Taylor, EDEMA, 1984, Raven Press, New York, 463-488.
10. Pearson, H, Clarke, T, Abbott, A, Knight, J, Cyranoski, D, SARS what have we learned? Nature, Volume 424, 23 January 2003, 121-126
11. Cramer DA, Adult respiratory distress syndrome, nd <http://blueprint.bluecrossmn.com/article/gale/100085006>
12. Ware LB, Matthay MA, The acute respiratory distress syndrome, New England Journal of Medicine, 342 18, 2000, 1334-1349.
13. Watkins LR, Maier SF, Neuropathic Pain: The Immune Connection, Pain Clinical Updates; International Association for the Study of Pain, March 2004, Volume XII, No 1
14. The Merck Manual of Diagnosis and Therapy, Section 6, Pulmonary Disorders, Chapter 67 Adult Respiratory Distress Syndrome, nd <http://www.merck.com/mrkshared/mmanual/section6/chapter67/67a.jsp>